

# THREE YEARS OF EXPERIENCE USING OCCLUTECH FIGULLA ASD OCCLUDER

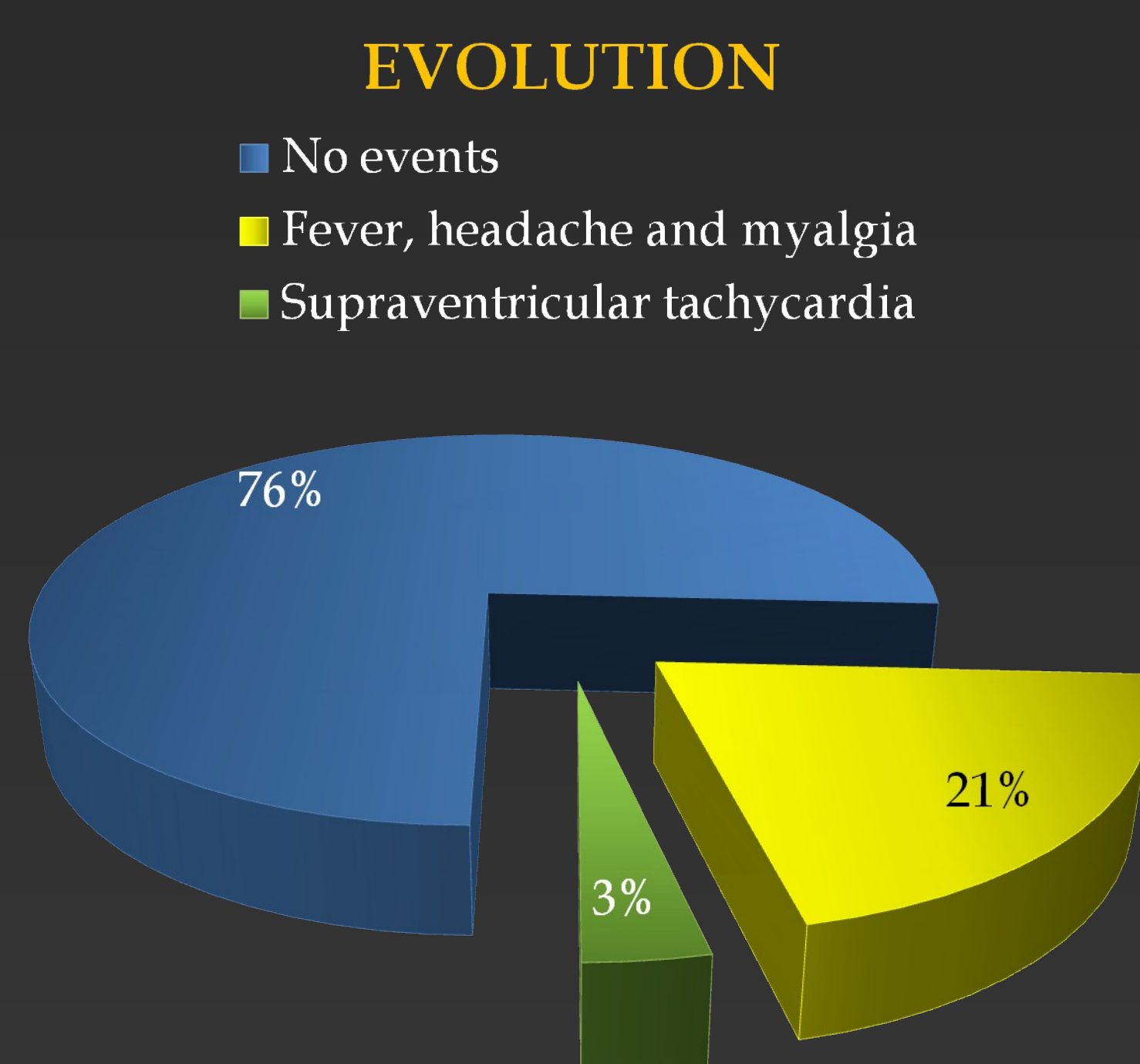
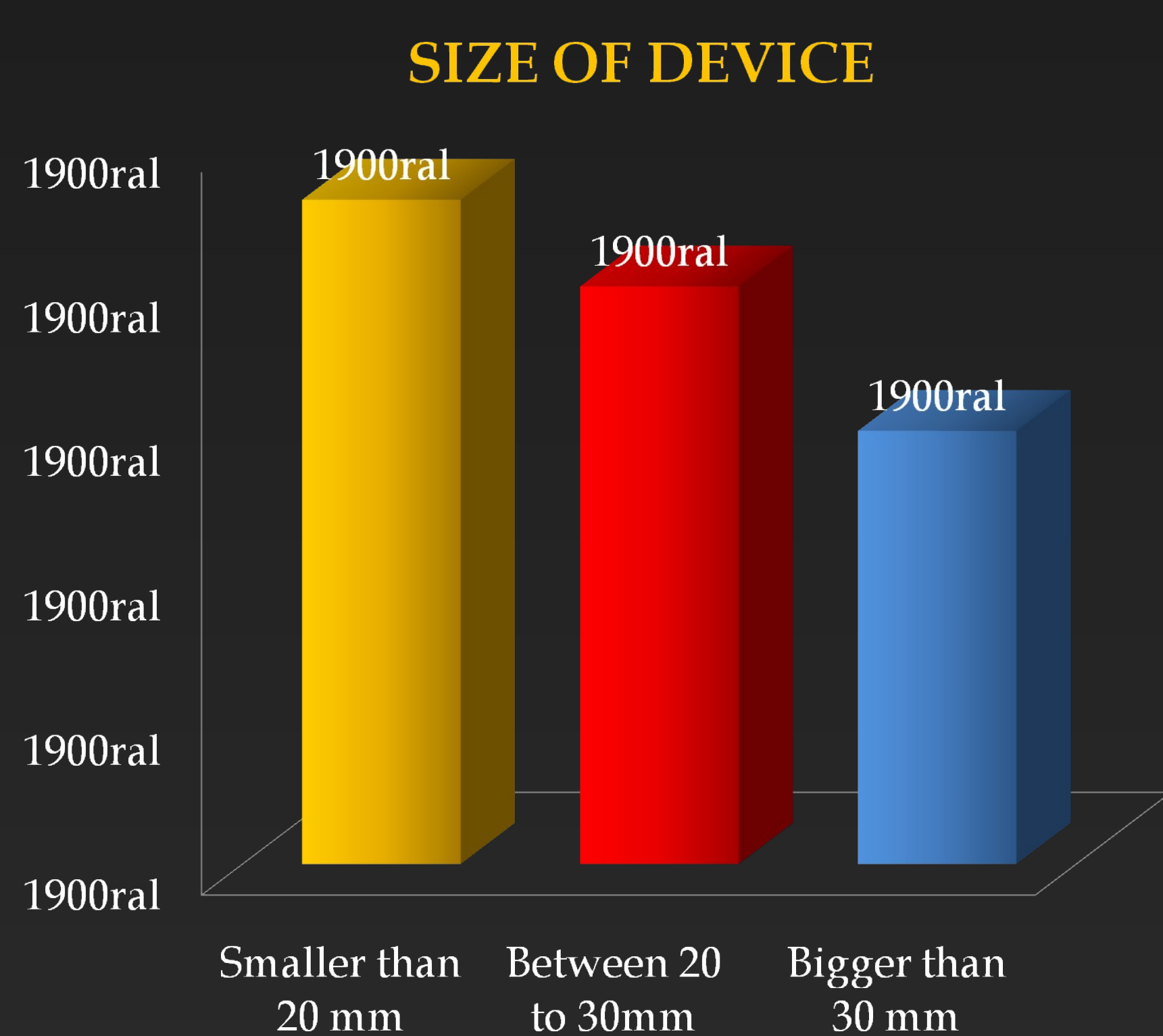
EDMUNDO CLARINDO OLIVEIRA e MARCO ANTÔNIO MOURA.  
Hospitals: Felicio Rocho, Life Center, Vera Cruz; BH, MG - BRAZIL.

**Introduction:** Closure of ASD has been proved to be safe and effective using different types of devices.

**Objective:** To describe a single-centre experience in the percutaneous occlusion of ASD using Occlutech device in 58 patients between March 2008 and February 2011.

**Methods:** Fifty eight patients with hemodynamic significant ASD were referred to our institution for percutaneous closure. Age 10 to 76 years (m=46), 63% females. All procedures were done by conscious sedation, femoral vein puncture, followed by TE ECHO and a single dose of prophylactic antibiotic. ASA was started at least five days before and continued for 6 months after device implant. TT ECHO was done: 1, 6 and 12 months after the intervention. Prophylaxis for endocarditis was recommended for six months.

FLUOROSCOPIC AND TEE ASPECT OF RELEASED OCCLUTECH DEVICE



**Results:** Device implant was done successfully in all patients. Twenty three devices smaller than 20mm, 26 between 20 to 30mm and 9 bigger than 30mm were implanted. Two patients had transient supraventricular tachycardia. Fever, headache and myalgia were observed in 12 patients, treated symptomatically, lasting from 7 to 28 days. All patients had significant reduction or normalization of RV dimensions and no residual shunt.

**Conclusions:** In this study, Occlutech ASD occluder showed to be safe, easy to manipulate and effective for closure of different sizes of defects